

blood

2000 96: 2037-2044

Solitary plasmacytoma of bone and asymptomatic multiple myeloma

Meletios A. Dimopoulos, Lia A. Moulopoulos, Alice Maniatis and Raymond Alexanian

Updated information and services can be found at:

<http://bloodjournal.hematologylibrary.org/cgi/content/full/96/6/2037>

Articles on similar topics may be found in the following *Blood* collections:

[Neoplasia](#) (4216 articles)

[Review Articles](#) (251 articles)

[Clinical Trials and Observations](#) (2630 articles)

Information about reproducing this article in parts or in its entirety may be found online at:

http://bloodjournal.hematologylibrary.org/misc/rights.dtl#repub_requests

Information about ordering reprints may be found online at:

<http://bloodjournal.hematologylibrary.org/misc/rights.dtl#reprints>

Information about subscriptions and ASH membership may be found online at:

<http://bloodjournal.hematologylibrary.org/subscriptions/index.dtl>

Blood (print ISSN 0006-4971, online ISSN 1528-0020), is published semimonthly by the American Society of Hematology, 1900 M St, NW, Suite 200, Washington DC 20036.

Copyright 2007 by The American Society of Hematology; all rights reserved.



Solitary plasmacytoma of bone and asymptomatic multiple myeloma

Meletios A. Dimopoulos, Lia A. Mouloupoulos, Alice Maniatis, and Raymond Alexanian

Most patients with multiple myeloma (MM) present with symptoms, have evidence of generalized disease, and require chemotherapy promptly to reduce the malignant clone. Some patients present with a local symptom from a single plasmacytoma

but no myeloma elsewhere. Such patients usually become free of symptoms after local radiotherapy. In patients with MM without symptoms, the diagnosis is made on the basis of screening laboratory tests. In patients with either solitary plasmacy-

toma of bone or asymptomatic MM, systemic treatment should be deferred until there is evidence of disease progression. (Blood. 2000;96:2037-2044)

© 2000 by The American Society of Hematology

Solitary bone plasmacytoma

Some patients with plasma cell myeloma present with a single painful bone lesion due to a monoclonal plasma cell infiltrate, and further studies show no evidence of myeloma elsewhere. In other cases, solitary bone plasmacytoma (SBP) may be discovered during roentgenographic studies for another condition or the patient presents with a painless swelling of the sternum, rib, or other bone. SBP affects less than 5% of patients with plasma cell myeloma.¹⁻³

Diagnosis

The diagnosis of SBP requires a solitary bone lesion, a biopsy of which shows infiltration by plasma cells; negative results on a skeletal survey; absence of clonal plasma cells in a random sample of bone marrow; and no evidence of anemia, hypercalcemia, or renal involvement suggesting systemic myeloma. Diagnostic criteria for SBP have varied over the years. Some older series included patients with 2 bone lesions or up to 10% bone marrow plasmacytosis. Other series excluded patients with disease that progressed within 2 years of diagnosis or in whom monoclonal protein persisted after local treatment.⁴⁻⁶

Recent advances have improved the precision of diagnosis. Flow cytometry studies and molecular detection of heavy- and light-chain gene rearrangements may reveal clonal plasma cells in the bone marrow of some patients who have no evidence of infiltration on light microscopy. Magnetic resonance imaging (MRI) is a noninvasive technique for sampling a large volume of bone marrow. We found that MRI revealed unsuspected involvement of bone marrow in 4 of 12 patients with apparent SBP.⁷ Liebross et al⁸ reported that among 23 patients with thoracolumbar SBP, multiple myeloma (MM) developed in 7 of 8 patients with a solitary lesion on plain radiographs alone but in only 1 of 7 patients who also had negative results on MRI of the spine ($P = .08$). Recommended diagnostic criteria for SBP that use on all sensitive techniques are shown in Table 1.

Clinical and laboratory features

Clinical features of SBP in 8 series with at least 25 patients each are shown in Table 2.^{1,8-14} Two thirds of patients were men, and their median age was approximately 55 years, about 10 years younger than patients with MM. SBP may involve any bone but most often affects the axial skeleton, particularly a vertebra. One study found that in 20% of patients with SBP, a rib, the sternum, the clavicle, or the scapula was involved.¹⁵ The most common presenting symptom was pain due to bone destruction, but patients with vertebral involvement may also have evidence of spinal cord or nerve root compression. A few patients with SBP present with symptoms and signs of demyelinating polyneuropathy.¹⁶ In evaluating such patients, the syndrome of polyneuropathy, organomegaly, endocrinopathy, M protein, and skin changes (POEMS) should be considered.

Like MM, SBP has a lytic appearance on plain radiographs. In most patients, the lesion is purely lytic and has a clear margin and a narrow zone of transition to normal surrounding bone. Computed tomography (CT) and particularly MRI depict the extent of SBP more clearly. The MRI appearance of SBP is consistent with that of a focal area of bone marrow replacement; the signal intensity is similar to muscle on T1-weighted images and hyperintense relative to muscle on T2-weighted images. An extraosseous soft-tissue component is often present and may impinge on the spinal cord or spinal nerve roots.⁷

Electrophoresis of serum and urine samples reveals monoclonal protein in 24% to 72% of patients with SBP (Table 2), although levels of the protein are much lower than those patients with MM. All patients with SBP should undergo serum and urine immunofixation even when electrophoresis results are normal, since monoclonal protein will not be detected in approximately one third of patients. The significantly higher incidence of nonsecretory disease in patients with SBP compared with patients with MM probably reflects the very low tumor load. With disease progression, monoclonal protein may be found in the serum or urine in some patients.¹⁷ The preserved levels of uninvolved immunoglobulins

From the Departments of Clinical Therapeutics and Radiology, University of Athens School of Medicine, Athens, Greece; the Department of Laboratory Hematology and Transfusion Medicine, University of Patras School of Medicine, Patras, Greece; and the Department of Lymphoma and Myeloma, University of Texas MD Anderson Cancer Center, Houston, TX.

Submitted March 2, 2000; accepted May 22, 2000.

Reprints: Meletios A. Dimopoulos, 227 Kifissias, Avenue Kifissia, Athens

14561 Greece; e-mail: mdimop@cc.uoa.gr.

The publication costs of this article were defrayed in part by page charge payment. Therefore, and solely to indicate this fact, this article is hereby marked "advertisement" in accordance with 18 U.S.C. section 1734.

© 2000 by The American Society of Hematology

Table 1. Recommended diagnostic criteria for solitary bone plasmacytoma

Single area of bone destruction due to clonal plasma cells
Normal marrow without clonal disease
Normal results on a skeletal survey and magnetic resonance imaging of the spine, pelvis, proximal femora, and humeri
No anemia, hypercalcemia, or renal impairment attributable to myeloma
Absent or low serum or urinary level of monoclonal protein and preserved levels of uninvolved immunoglobulins

observed in virtually all patients with SBP provide further evidence that the tumor load is low.

Treatment and response

Definitive local radiotherapy is the treatment of choice for SBP. Treatment fields should be designed to encompass all disease shown by MRI or CT scanning and should include a margin of normal tissue. For spinal lesions, the margin should include at least one uninvolved vertebra. After adequate radiotherapy, virtually all patients have relief of symptoms. The radiologic response to radiation therapy may include sclerosis and bone remineralization in up to 50% of patients followed up with plain radiography assessments.^{8,10} On MRI images, abnormalities of the bone marrow and an accompanying soft-tissue mass may persist even after successful treatment.⁸ Local control, defined as long-term clinical and radiographic stability, has been achieved in at least 90% of cases (Table 3).^{1,8-10,14} Mendenhall et al¹⁸ reported a 6% incidence of local failure with doses of at least 4000 cGy and a 31% incidence with lower doses. Frassica et al¹⁴ did not observe local failure when the radiotherapy dose was 4500 cGy or larger. There is evidence of a higher proportion of local failures in patients with spinal lesions.^{5,14} Although the optimal dose of radiotherapy has not been established by prospective studies, most authors reporting series agree that a dose of approximately 4500 cGy (4000 cGy for vertebral lesions) provides the best local control without producing serious toxicity.

In most patients, the monoclonal protein is reduced markedly after completion of local radiotherapy. Serial and frequent measurements of myeloma protein for at least 6 months after treatment are required to confirm disease radiosensitivity. The rate of reduction may be slow and a continuous decrease in the protein may be observed for several years.¹⁷ The monoclonal protein disappears in a minority of patients (20%-50%), suggesting that all disease was included within the radiotherapy field. The likelihood of disappearance of monoclonal protein is higher in patients in whom the pretreatment value is low. In the series of Liebross et al,⁸ the paraprotein persisted in all patients with a serum level above 10 g/L and there was no dose-response relation between radiation dose and disappearance of monoclonal protein.⁸ In many patients, the monoclonal protein persists despite adequate radiotherapy, indicat-

Table 3. Outcome after radiotherapy in patients with solitary bone plasmacytoma

Series	No. of patients	Local recurrence (% of patients)	10-y disease-free survival (% of patients)	Median survival (y)
Knowing et al ¹	25	0	16	7.5
Brinch et al ⁹	25	0	Not available	12.0
Bolek et al ¹⁰	27	4	46	10.0
Frassica et al ¹⁴	46	11	25	9.3
Liebross et al ⁸	57	4	42	11.0

ing the presence of tumor beyond the field of radiation. The condition of these patients may remain stable for a long time, and further treatment should be deferred until there is clear progression of the plasma cell disorder.

Although most patients with SBP of the spine can be treated with radiotherapy alone, some patients in whom the diagnosis of SBP has not yet been made present with or have rapid development of neurologic dysfunction that requires laminectomy before radiotherapy. An anterior approach may be preferred because posterior procedures do not address the source of the impingement and may not reliably relieve neurologic compromise. Surgical intervention may also be necessary in patients with vertebral instability.⁶ Surgical fixation of a pathologic fracture of a long bone may also be required.

Course of the disease

The outcome in patients with SBP in 5 series with at least 25 patients each who received local radiotherapy without adjuvant chemotherapy is shown in Table 3. In patients with SBP, the most common pattern of progression consists of new bone lesions, rising myeloma protein level, and development of marrow plasmacytosis. In some patients, new bone lesions with normal intervening marrow develop, consistent with a "macrofocal" pattern of growth.^{13,14,19} The median time to progression is 2 to 3 years, but MM has developed in a few patients as long as 15 years after radiotherapy. Most patients with early disease progression presumably had occult generalized disease at diagnosis, whereas some patients with an apparent late recurrence may have had indolent growth for many years or, possibly, development of a second primary plasma cell neoplasm. The lower median age of patients with SBP compared with those with MM and the later development of MM in most patients with SBP suggest that SBP represents an early manifestation of MM in some cases. On the other hand, the condition of some patients has remained stable for more than a decade despite persistence of low-level monoclonal protein. Such patients may have had reversion to stable monoclonal gammopathy of undetermined significance (MGUS) that may have preceded the SBP. When MM evolves, most patients have features of low-tumor-mass disease, a high rate of response to chemotherapy, and

Table 2. Characteristics of patients with solitary bone plasmacytoma

Series	No. of patients	Median age (y)	Male patients (%)	Spine disease (% of patients)	Monoclonal protein (% of patients)
Knowing et al ¹	25	50	68	32	24
Brinch et al ⁹	25	56	72	68	61
Bolek et al ¹⁰	27	55	70	33	52
Jackson and Scarffe ¹¹	32	62	59	72	54
Galièni et al ¹²	32	52	81	40	47
Holland et al ¹³	32	60	70	34	Not available
Frassica et al ¹⁴	46	56	65	54	54
Liebross et al ⁸	57	53	69	40	72

prolonged survival.^{8,14,20} Thus, the median overall survival time in patients with SBP averages 10 years, and 10% to 20% of patients die of unrelated causes (Table 3 and Figure 1).

In a few patients with SBP, recurrent "solitary" plasmacytomas develop after adequate radiotherapy has been administered to the primary lesion. Careful assessments of the bone marrow, a bone survey, and MRI evaluations of the axial skeleton still fail to show evidence of MM. When isolated lesions develop at long intervals (ie, more than 2 years), radiotherapy alone may be followed by prolonged clinical stability. When new lesions develop at shorter intervals and are accompanied by other signs that suggest MM (falling levels of uninvolved serum immunoglobulins and new abnormalities on MRI studies), systemic treatment for MM may be justified. If there is doubt, longer follow-up without chemotherapy should clarify the clinical course.

Prognostic factors

With more sensitive staging procedures, the diagnosis of SBP should become less common, but the fraction of patients with prolonged stability, or even cure, should increase. In some series, no factors predictive of systemic recurrence could be identified.^{1,3,14,20,21} There was no relation between the dose of local radiotherapy and the likelihood of distant progression. Jackson and Scarffe¹¹ suggested that osteopenia and low levels of uninvolved immunoglobulins were adverse prognostic factors. Immunoparesis was associated with an increased risk of progression in another study,¹² and all 3 patients with low levels of uninvolved immunoglobulins in the MD Anderson study had disease progression¹⁸ (again, low levels of uninvolved immunoglobulins usually indicate occult MM). The size of the lesion appeared to predict conversion to MM in one series.¹³ In other series, relapse rates were higher in older patients or in those with axial lesions.⁵ In several series, disappearance of abnormal protein after local radiotherapy was associated with a high probability of long-term stability.^{2,12,22} An update of the MD Anderson series⁸ reported that among 11 patients with disappearance of myeloma protein, MM developed in only 2 (after 4 and 12 years, respectively), whereas MM developed in 57% of patients with persistent monoclonal protein and 63% of those with nonsecretory disease ($P = .02$; Figure 1). High levels of monoclonal protein and depression of uninvolved immunoglobulins raise major concerns regarding the diagnosis of SBP.

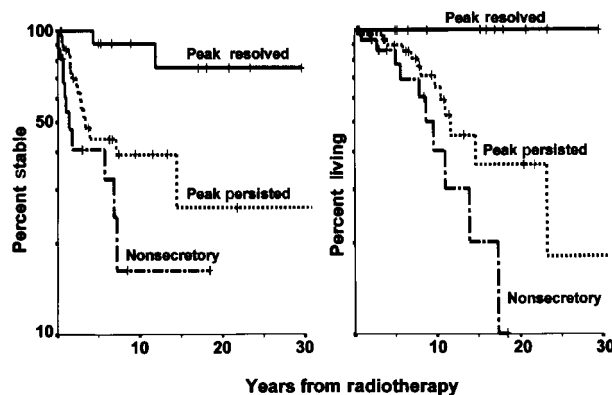


Figure 1. Remission and survival in solitary bone plasmacytoma. The panel on the left shows the remission time in 61 patients with solitary plasmacytoma of bone treated at the MD Anderson Cancer Center, according to disappearance and persistence of myeloma protein or nonsecretory myeloma. The panel on the right shows cause-specific survival after radiotherapy in the same groups of patients.

The role of adjuvant chemotherapy

In several series, chemotherapy was administered after completion of local radiation treatment. Mayr et al²³ found that adjuvant chemotherapy may prevent progression to MM. Holland et al¹³ found that chemotherapy did not affect the overall rate of progression to myeloma but that adjuvant treatment changed the median time to progression from 29 to 59 months. In most other series, adjuvant chemotherapy had no beneficial effect.^{3,12,15} On the basis of the available data, we believe that adjuvant chemotherapy should not be administered to patients with SBP. Use of systemic chemotherapy or corticosteroids may obscure recognition of patients with disappearance of myeloma protein after radiotherapy who may be cured. Furthermore, early exposure to systemic treatment may hasten the evolution of resistant subclones and thereby restrict later therapeutic options, when they may be more useful. Moreover, in one series, secondary leukemia developed in 4 of 7 patients with SBP who received adjuvant melphalan-based chemotherapy after completion of radiotherapy.¹⁹

Asymptomatic MM

Definition

In recent years, many patients without any symptoms attributable to MM have been given a diagnosis of the disease by means of screening tests or during an investigation of another disorder. Coincidental discovery of abnormal laboratory values, especially an increased serum protein level, led to the recognition of MM. The concept of smoldering MM (SMM) or indolent myeloma was introduced by Kyle and Greipp²⁴ and Alexanian¹⁷ 20 years ago. These investigators defined a group of patients with myeloma who had a stable clinical course for several years before chemotherapy was necessary.

Most patients with asymptomatic myeloma have stage I disease according to the Durie and Salmon criteria²⁵ and features of low-tumor-mass disease according to the MD Anderson criteria²⁶ (serum myeloma protein below 45 g/L and hemoglobin level above 105 g/L). Distinguishing between asymptomatic myeloma and MGUS may be difficult. The latter condition is a relatively common plasma cell dyscrasia characterized by a serum monoclonal protein level below 30 g/L, less than 5% plasma cells in the bone marrow, no or only a small amount of urinary protein on Bence Jones assessment, absence of lytic bone lesions, and no related hypercalcemia, renal impairment, or anemia.²⁷ When at least one lytic lesion is present, marrow plasmacytosis exceeds 15%, the serum monoclonal protein level is below 30 g/L on standard electrophoresis, or the Bence Jones urinary protein value is above 150 mg/day, asymptomatic MM is very likely. In patients with less than 5% marrow plasma cells, a serum monoclonal protein level below 20 g/L, a Bence Jones urinary protein value below 50 mg/day, and preserved uninvolved serum immunoglobulins, MGUS is highly likely (Table 4).²⁸ Many patients do not meet all the criteria for either disorder, and other studies may be useful for differentiating between the diseases. Abnormal results on MRI, an increased plasma cell labeling index, or the presence of monoclonal circulating plasma cells in blood provides strong evidence that myeloma is either present or will soon develop.²⁷ If there is doubt, long-term follow-up is required for clarification.

Some asymptomatic patients present with myeloma of intermediate stage, indicated by a serum myeloma protein level of at least 45 g/L or a hemoglobin level under 105 g/L. Despite the absence of

Table 4. Comparison of monoclonal gammopathy of undetermined significance and asymptomatic myeloma

Characteristic	MGUS	Asymptomatic myeloma
Monoclonal protein	< 30 g/L	> 20 g/L in 85%
Marrow plasma cells	< 10%	> 10%
Uninvolved immunoglobulins	Preserved in 80%	Depressed in 90%
Urinary protein (Bence Jones)	None or < 50 mg/d	> 50 mg/d in 35%
Spine MRI results	Normal	Abnormal in 40%

MGUS indicates monoclonal gammopathy of undetermined significance; MRI, magnetic resonance imaging.

symptoms, patients with such disease features should be treated soon after diagnosis because disease complications are likely to occur within 12 months.²⁹ We will therefore focus here on patients with asymptomatic MM of low tumor mass (stage I).

Incidence

The incidence of asymptomatic MM varies among series and has increased during the past decade. Between October 1974 and December 1991, among the 638 consecutively seen, previously untreated patients with MM evaluated at MD Anderson Cancer Center, 95 patients (15%) had asymptomatic myeloma of low tumor mass.³⁰ Riccardi et al³¹ reported that the percentage of asymptomatic patients who received a diagnosis by chance increased from 14% during the period 1972-1986 to 34% during the period 1987-1990. From August 1984 until December 1986 in a Norwegian health region with approximately 820 000 people, MM was found in 162 people, 71 (44%) of whom were asymptomatic.³² Age, sex, and myeloma-type distribution were similar in symptomatic and asymptomatic patients.

Treatment at diagnosis

Two prospective randomized trials assessed the role of systemic chemotherapy in asymptomatic MM. Hjorth et al³³ randomly assigned 50 patients with asymptomatic myeloma stage I to immediate treatment with melphalan and prednisone or to deferred therapy, in which treatment with the same agents was started at the time of disease progression. No differences between the 2 groups in response rate, response duration, or survival were observed. A similar study with 44 patients was conducted by Grignani et al,³⁴ who reported similar survival times of 58 months and 54 months, respectively, in patients randomly assigned to deferred or immediate treatment. Although neither study had enough patients to detect small differences, it is unlikely that immediate chemotherapy will prolong survival. Furthermore, in studies of other low-grade lymphoproliferative disorders, there was evidence that early treatment of asymptomatic patients does not prolong survival.³⁵

Definition of progressive disease

Although almost all researchers who have reported series agree that patients with asymptomatic myeloma of low tumor mass should be followed up without treatment until there is evidence of disease progression, criteria for progressive tumor growth have not been clearly established. In 3 consecutive series at the MD Anderson Cancer Center, progressive disease was defined by an elevation of serum myeloma protein to at least 5.0 g/dL, an unequivocal increase in the size or number of bone lesions, or an obvious complication of myeloma, such as a pathologic fracture, anemia, hypercalcemia, or impairment of renal function. The myeloma protein level of 50 g/L was chosen after preliminary assessment showed that an increase to this value was nearly always associated with early subsequent morbidity. Wisloff et al³⁶ initiated treatment

in asymptomatic patients if at least one of the following complications occurred: skeletal pain or pathologic fracture, osteolytic destruction in weight-bearing bones, hemoglobin level below 90 g/L, renal impairment, hypercalcemia, proteinuria (Bence Jones value > 4 g/24 hours), neurologic symptoms, or recurring infections. Facon et al³⁷ defined progression as evolution of asymptomatic stage I to Durie and Salmon stage II or III.

Prognostic features for disease progression

Unless death due to another condition occurs, all patients with asymptomatic myeloma will eventually have disease progression and require treatment. Although the median time to progression is approximately 3 years, identification at diagnosis of patients with a high or low likelihood of early progression (ie, within 12 or 18 months) is important. Obviously, follow-up in patients with a high likelihood should be more frequent and stringent than that in patients with a low likelihood.

Several studies have described prognostic factors that identified patients in whom the disease was likely to progress early. The results of 3 large studies in which a multivariate analysis was performed are shown in Table 5.^{30,36,37} Some patients with asymptomatic bone lesions were included in these studies, and the lesions were associated with a median time to progression of less than 12 months.^{30,36} However, surveillance is not appropriate in such patients, who should be treated soon after diagnosis. Other independent variables associated with earlier progression were greater bone marrow plasmacytosis, higher serum monoclonal protein level, lower hemoglobin value, and the presence of proteinuria on Bence Jones assessment.^{30,36,37}

The plasma cell labeling index and the peripheral blood B-cell labeling index (using tritiated thymidine or bromodeoxyuridine) are low in patients with SMM, indicating a low proliferative index. Studies at the Mayo Clinic showed that patients with asymptomatic myeloma in whom either index is more than 0.4% are likely to have progression to symptomatic myeloma within 12 months.^{38,39} A more recent study at the same institution evaluated the number and labeling index of circulating peripheral blood monoclonal plasma cells (PBPC) in 17 patients with newly diagnosed SMM. These investigators found that the median time to progression in patients with abnormal PBPC (defined as an increase in the number or proliferative rate of circulating PBPC) was 0.75 years, whereas it was 2.5 years for those patients without abnormal PBPC ($P < .01$).⁴⁰

In several studies, MRI was performed in patients with asymptomatic myeloma without bone lesions on plain radiographs (Table 6).⁴¹⁻⁴³ Abnormal MRI results occurred in 29% to 50% of patients and were associated with earlier progression in all series. In a study of 55 patients with asymptomatic myeloma, Mariette et al⁴³ conducted a multivariate analysis of variables associated with

Table 5. Characteristics of patients and prognostic factors for progression of asymptomatic myeloma in 3 series

	Wisloff et al ³⁶	Dimopoulos et al ³⁰	Facon et al ³⁷
No. of patients	71	95	91
Lytic lesions (%)	15	18	4
Median time to progression (mo)	26	26	48
Adverse prognostic factors			
Bone lesions	Yes	Yes	Yes
Bone marrow plasmacytosis	Yes	No	Yes
Serum monoclonal protein	No	Yes	Yes
Urinary protein (Bence Jones)	No	Yes	No
Mild anemia	No	No	Yes

disease progression and demonstrated that the only significant factors were abnormal MRI results and the presence of at least 20% plasma cells in the bone marrow.

An analysis at the MD Anderson Cancer Center that excluded asymptomatic patients with bone lesions on plain radiographs revealed 3 dominant prognostic factors predictive of early progression: serum monoclonal protein level above 30 g/L, IgA heavy-chain type, and Bence Jones protein excretion value above 50 mg/day. The presence of 2 or more of these features identified high-risk disease with a median time to progression of 17 months. The presence of only one adverse feature was associated with a median time to progression of 40 months, whereas the absence of all adverse variables was associated with prolonged stability (median time to progression of 95 months).⁴⁴ The same study concluded that MRI of the spine was particularly useful in patients with an intermediate time to progression; abnormal MRI results were observed in 40% of such patients and were associated with a median time to progression of 21 months (Figure 2).

Outcome after progression

All patients with tumor progression require systemic treatment. Response rates in patients who initially presented without symptoms were similar to those in symptomatic patients treated at diagnosis, as were the median survival times after treatment.^{26,30,36} The similar outcomes indicated that drug-resistant tumor cells did not expand during the surveillance period. After initiation of chemotherapy for disease progression, survival times in previously asymptomatic patients were similar among groups of patients, despite widely different times to progression.^{30,37} Asymptomatic patients with a low risk of progression had a median overall survival time longer than 6 years.^{30,37} This indicated that the extent of disease at diagnosis and the rate of tumor growth before chemotherapy had a major impact on the overall survival of patients with asymptomatic myeloma.

Biologic features of asymptomatic myeloma and MGUS

Analysis of several series of patients with asymptomatic myeloma indicates that patients with this disease represent a heterogeneous group. Although one fourth of patients require treatment within a year after diagnosis, the condition of others may remain stable for 5 years or longer. Clinical and laboratory features that predict prolonged disease stability have been identified at diagnosis, but the factors that maintain disease dormancy and those that are responsible for disease progression are not known.

A substantial amount of knowledge regarding the pathogenetic

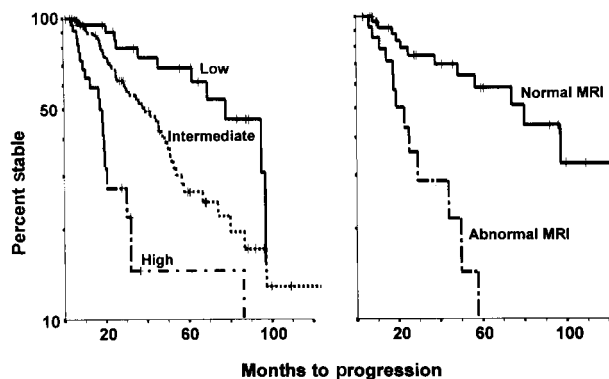


Figure 2. Progression of asymptomatic myeloma. The panel on the left shows the variable times to disease progression in 123 asymptomatic patients with multiple myeloma at the MD Anderson Cancer Center, according to risk status defined by the presence of 0, 1, or 2 or more of the following abnormalities: monoclonal protein level above 30 g/L, IgA myeloma protein type, and urinary protein level above 50 mg/day on Bence Jones assessment ($P < .01$). The panel on the right shows the variable times to disease progression in 43 asymptomatic patients considered at intermediate risk on the basis of magnetic resonance imaging results ($P < .01$).

mechanisms of myeloma has accumulated in recent years. In addition, studies of patients with MGUS have revealed links between this disorder and myeloma. SBP and asymptomatic myeloma could be considered intermediate steps in the evolution from MGUS to myeloma.^{45,46}

Studies of MGUS and myeloma have focused on cytogenetic factors, cytokines, adhesion molecules, and angiogenesis. Similar studies of the plasma cells of SPB or of asymptomatic myeloma are rare; however, because at least one third of patients with myeloma have disease evolution after a history of MGUS, it seems reasonable to assume that there are similar “markers” of tumor growth in all clonal plasma cell disorders.⁴⁷

Cytogenetic studies

Initial studies of plasma cells in patients with MGUS rarely showed chromosomal abnormalities. More recently, studies using fluorescent in situ hybridization confirmed the presence of abnormalities in MGUS similar to those in overt MM. Calasanz et al⁴⁸ reported chromosomal abnormalities in 25% of MGUS clones, Fonseca et al⁴⁹ found 14q32 abnormalities in 66% of MGUS cases, and abnormal IgH recombinations were observed by Avet-Loiseau et al⁴⁶ in 58% of patients with MGUS and 59% with myeloma. More specifically, 14q32 abnormalities were observed in 46% of patients with MGUS or SMM and were present in the majority of clonal plasma cells. These observations support the conclusion that mutations at the immunoglobulin heavy-chain gene locus 14q32 represent the primary genetic abnormality in clonal plasma cell dyscrasias and that additional subsequent abnormalities lead to the evolution of MM.^{50,51} The t(11;14)(q13;q32) occurs in 15% of MGUS or SMM patients, an incidence similar to that in myeloma; however, t(4;14)(p16;q32) occurs in 2% of MGUS or SMM patients but in 12% of patients with overt myeloma.⁴⁷

Deletions of chromosome 13, which confer a poor prognosis in myeloma, were found in 39% of myeloma cases but in 83% of myeloma cases that evolved from MGUS and in 4 of 19 patients (20%) with stable MGUS.⁴⁶ In addition, a monoallelic deletion of the 13q14 region was found in 21% of patients. The deletion was present in the majority of clonal plasma cells in patients with SMM or overt myeloma but in fewer clones in those with MGUS⁴⁶ (Table 7). Chromosomal aneuploidy (trisomies 3, 7, 9, and 11) was

Table 6. Prognostic importance of MRI in asymptomatic myeloma

Series	No. (%) of patients	Median time to progression (mo)	P value
Moulopoulos et al ⁴¹			
Normal MRI results	19 (50)	43	
Abnormal MRI results	19 (50)	16	<.01
Vande Berg et al ⁴²			
Normal MRI results	17 (71)	32	
Abnormal MRI results	7 (29)	10	<.0001
Mariette et al ⁴³			
Normal MRI results	38 (69)	Not reached	
Abnormal MRI results	17 (31)	Not reached	<.0001

MRI indicates magnetic resonance imaging.

Table 7. Chromosomal abnormalities in plasmacytic proliferations

Abnormality	MGUS (%)	Asymptomatic myeloma (%)	Overt myeloma (%)	Reference
14q32	58	77	59	Avet-Loiseau et al ⁴⁵
t(11;14)	15	15	15	Avet-Loiseau et al ⁴⁶
t(4;14)	2	2	12	Avet-Loiseau et al ⁴⁶
-13/13q-	21	23	36	Avet-Loiseau et al ⁴⁵

Values are percentages of patients with the abnormality.

reported in 50% of patients with MGUS and 13q14 abnormalities in 46%.⁵²

Cytokines

Interleukin (IL) 6 is considered the principal growth factor in the progression of MM. Significantly elevated serum IL-6 levels were found in 3% of patients with MGUS or SMM, 35% with overt MM, and 100% of plasma cell leukemias.⁵³ IL-6 receptor (IL-6R) consists of a membrane protein, CD126, and a signal-transducing molecule, CD130. Expression of IL-6R components in MGUS and MM was studied by Barille et al.⁵⁴ CD126 was detectable in 50% of patients with either MGUS or MM and did not change during disease progression, whereas CD130 was expressed in 43% of MM patients at diagnosis and in 88% at relapse. Elevations of serum soluble IL-6R were also reported in both MGUS and MM.^{55,56}

IL-1 β and tumor necrosis factor α (TNF- α) are bone-resorbing cytokines and therefore of interest in research on plasmacytic neoplasms. Studies using sensitive techniques suggested that TNF- α is produced by the plasma cells of both myeloma and MGUS, whereas IL-1 β messenger RNA (mRNA), but not the protein, could be detected.⁵⁷ In a similar study, Lacy et al⁵⁸ detected IL-1 β mRNA in 49 of 51 patients with active myeloma, 7 of 7 with SMM, 5 of 21 with MGUS, and 0 of 5 healthy controls. Bone lesions were present in 40 patients with MM, and all had detectable IL-1 β mRNA. Serial measurements in patients with MGUS may clarify whether the presence of IL-1 β mRNA is predictive of progression of MGUS to myeloma.

IL-10 is also increased in patients with plasma cell leukemia or solitary plasmacytoma, with growth factor activity mediated through a gp130 cytokine, oncostatin M.⁵⁹ Therefore, although cytokines may not be an etiologic factor in myeloma, they are important in the proliferation of the malignant clone.

Surface markers and adhesion molecules

The phenotypes of plasma cells in cases of MGUS and myeloma are also of interest. Ocqueteau et al⁶⁰ studied 76 patients with MGUS, 65 with MM, and 10 control subjects by using a large panel of monoclonal antibodies against plasma cell-related antigens. They concluded that residual polyclonal plasma cells are always present in MGUS but only rarely present in MM. CD44, a polymorphic glycoprotein involved in adhesion, and variant isoforms (CD44v) were studied in patients with myeloma by van Driel et al.⁶¹ Both CD44v9⁺ and CD44v10⁺ were expressed on plasma cells of healthy persons, whereas CD44v9⁻v10⁺ was expressed in patients with stable myeloma and CD44v9⁺v10⁻ in patients with progressive myeloma. Assessment of certain adhesion molecules, such as CD56, can differentiate MGUS (CD56⁻) from myeloma (CD56⁺).⁶²

Angiogenesis

The role of angiogenesis in tumor progression and the potential of antiangiogenic substances as therapy have recently received much attention. Angiogenesis correlates with plasma cell growth (S-phase fraction) in both MGUS and MM.⁶³ Levels of angiogenic basic fibroblast growth factor 2 protein in plasma cell extracts from patients with active MM were higher than those from patients with nonactive myeloma and MGUS. Also, levels of matrix metalloproteinase-2 mRNA and protein were higher in patients with active MM than in those with responding MM or stable MGUS.⁶⁴ Di Raimundo et al⁶⁵ reported increased levels of vascular endothelial growth factor (VEGF) in plasma of both the peripheral blood and bone marrow in patients with active MM, whereas in patients with MGUS or early myeloma, elevated VEGF levels were observed only in bone marrow plasma.

Bone marrow microvessel area was increased in patients with active MM compared with control subjects but not in patients with nonactive MM or MGUS. Furthermore, conditioned medium from plasma cell cultures showed angiogenic potential in 76% of active myeloma cases, 33% of nonactive cases, and 20% of MGUS cases.⁶³ Nevertheless, no direct correlations have so far been found between levels of these angiogenic factors and the extent of neovascularization in bone marrow of myeloma patients. Studies of other factors with angiogenic potential, such as VEGF, TNF- α , transforming growth factor β , and IL-1 β , are under way.

On the basis of the findings described above, clinical trials of thalidomide (an antiangiogenic drug) in the treatment of myeloma were begun. Results were encouraging, although there was no correlation between marrow vascularization and response.⁶⁶ Thalidomide possibly also acts by mechanisms other than antiangiogenesis, such as a direct antitumor effect; by altering regulatory cytokines; or by means of its immunomodulatory effects.⁶⁷

Other factors

Other features may be involved in the transition from the premalignant to the malignant phase of plasmacytic proliferation. Using a flow cytometric method, Witzig et al⁶⁸ defined a plasma cell growth index and a plasma cell apoptotic index and compared marrow from patients with MGUS, SMM, and MM. They found a decrease in apoptosis during progression from MGUS to SMM and MM, without a significant increase in proliferation.

With regard to bone disease, Bataille et al⁶⁹ found excessive bone resorption on bone biopsy in 16% of patients with low-risk MGUS, 46% with high-risk MGUS, 79% with SMM, and 93% with MM. Excessive bone resorption was present in 52% of patients with MGUS in whom MM subsequently developed but in only 4% of those with stable MGUS.

Finally, hypogammaglobulinemia, a typical finding in overt myeloma, may also be present in earlier phases of the disease. A decrease in levels of uninvolved immunoglobulins was found in 20% to 30% of MGUS patients.⁷⁰ CD5⁺ B cells affect immunoglobulin production, and in a study by Paglieroni et al,⁷¹ the numbers of these cells were found to increased in 7 of 10 MGUS patients who had progression to MM but in none of 11 patients with stable MGUS. Also, 8 of 8 patients with localized plasmacytoma and increased CD5⁺ B cells had progression to MM or recurrence of plasmacytoma, whereas 0 of 9 with normal CD5⁺ B cells numbers remained healthy. It was hypothesized that these suppressive cells may have a role in disease regulation in addition to their role in hypogammaglobulinemia.

Future directions

In most patients with SPB and residual myeloma protein or with asymptomatic myeloma and increased risk factors, overt MM develops within 3 years. Such patients are candidates for trials of new agents that are rational and entail a low likelihood of serious toxicity. This applies to drugs that are active in vitro or against rodent plasmacytomas or human B-cell leukemias and lymphomas. For example, we confirmed some of the earliest clinical evidence of activity for interferon α , dexamethasone, and paclitaxel; we failed to observe a benefit with all-*trans* retinoic acid; and we are now assessing the value of thalidomide. In view of the projected long survival of most patients, more intensive therapy supported by

autologous stem cell transplantation should be deferred until MM becomes more evident, when the potential clinical benefit clearly outweighs the risks. The prophylactic role of bisphosphonates in maintaining bone mineralization appears less clear, since no controlled studies have been conducted in patients without lytic bone lesions or in very early phases of disease. One can envision randomized multicenter trials in selected patients with asymptomatic myeloma and reduced bone density.

Acknowledgments

We thank Kay Delasalle and Dimitra Gika for technical and secretarial assistance.

References

1. Knowling MA, Harwood AR, Bergsagel DE. Comparison of extramedullary plasmacytomas with solitary and multiple plasma cell tumors of bone. *J Clin Oncol*. 1983;1:255-262.
2. Dimopoulos MA, Goldstein J, Fuller L, Delasalle K, Alexanian R. Curability of solitary bone plasmacytoma. *J Clin Oncol*. 1992;10:587-590.
3. Shih LY, Dunn P, Leung WM, Chen WJ, Wang PN. Comparison between extramedullary plasmacytoma and solitary plasmacytoma of bone. *Br J Cancer*. 1995;71:128-133.
4. Corwin J, Lindberg RD. Solitary plasmacytoma of bone vs. extramedullary plasmacytoma and their relationship to multiple myeloma. *Cancer*. 1979;43:1007-1013.
5. Bataille R, Sany J. Solitary myeloma: clinical and prognostic features of a review of 114 cases. *Cancer*. 1981;48:845-851.
6. McLain RF, Weinstein JN. Solitary plasmacytomas of the spine: a review of 84 cases. *J Spinal Disord*. 1989;2:69-74.
7. Mouloupos LA, Dimopoulos MA, Weber D, Fuller L, Libshitz HI, Alexanian R. Magnetic resonance imaging in the staging of solitary plasmacytoma of bone. *J Clin Oncol*. 1993;11:1311-1315.
8. Liebross RH, Ha CS, Cox JD, Weber D, Delasalle K, Alexanian R. Solitary bone plasmacytoma: outcome and prognostic factors following radiotherapy. *Int J Radiat Oncol Biol Phys*. 1998;44:1063-1067.
9. Brinch L, Hannisdal E, Foss Abrahamsen A, Kvaloy S, Langholm R. Extramedullary plasmacytomas and solitary plasma cell tumours of bone. *Eur J Haematol*. 1990;44:131-134.
10. Bolek TW, Marcus RD, Mendenhall NP. Solitary plasmacytoma of bone and soft tissue. *Int J Radiat Oncol Biol Phys*. 1996;36:329-333.
11. Jackson A, Scarffe JH. Prognostic significance of osteopenia and immunoparesis at presentation in patients with solitary myeloma of bone. *Eur J Cancer*. 1990;26:363-371.
12. Galienu P, Cavo M, Avvisati G. Solitary plasmacytoma of bone and extramedullary plasmacytoma: two different entities? *Ann Oncol*. 1995;6:687-691.
13. Holland J, Trenkner DA, Wasserman TH, Fineberg B. Plasmacytoma. Treatment results and conversion to myeloma. *Cancer*. 1992;69:1513-1517.
14. Frassica DA, Frassica FJ, Schray MF, Sim FH, Kyle RA. Solitary plasmacytoma of bone: Mayo Clinic experience. *Int J Radiat Oncol Biol Phys*. 1989;16:43-48.
15. Burt M, Karpeh M, Ukoha O, et al. Medical tumors of the chest wall: solitary plasmacytoma and Ewing's sarcoma. *J Thorac Cardiovasc Surg*. 1993;105:89-96.
16. Schindler OS, Briggs TW, Gillies SA. Bilateral demyelinating neuropathy in a solitary lytic and sclerotic myeloma of the proximal humerus. *Int Orthop*. 1997;21:59-61.
17. Alexanian R. Localized and indolent myeloma. *Blood*. 1980;56:521-526.
18. Mendenhall CM, Thar TL, Million RR. Solitary plasmacytoma of bone and soft tissue. *Int J Radiat Oncol Biol Phys*. 1980;6:1497-1501.
19. Delauche-Cavallier MC, Laredo JD, Wybier M, et al. Solitary plasmacytoma of the spine. Long-term clinical course. *Cancer*. 1988;61:1707-1714.
20. Chak LY, Cox RS, Bostwick DG, Hoppe TT. Solitary plasmacytoma of bone: treatment, progression and survival. *J Clin Oncol*. 1987;5:1811-1815.
21. Jyothirmayi R, Gangadharan VP, Nair MK, Rajan B. Radiotherapy in the treatment of solitary plasmacytoma. *Br J Radiol*. 1997;70:511-516.
22. Ellis PA, Colls BM. Solitary plasmacytoma of bone: clinical features, treatment and survival. *Hematol Oncol*. 1992;10:207-211.
23. Mayr NA, Wen BC, Hussey DH, et al. The role of radiation therapy in the treatment of solitary plasmacytomas. *Radiother Oncol*. 1990;17:293-303.
24. Kyle RA, Greipp P. Smoldering multiple myeloma. *N Engl J Med*. 1980;302:1347-1349.
25. Durie BG, Salmon SE. A clinical staging system for multiple myeloma. *Cancer*. 1975;36:842-854.
26. Alexanian R, Barlogie B, Dixon D. Prognosis of asymptomatic multiple myeloma. *Arch Intern Med*. 1988;148:1963-1965.
27. Kyle RA, Rajkumar SV. Monoclonal gammopathies of undetermined significance. *Hematol Oncol Clin North Am*. 1999;13:1181-1202.
28. Alexanian R, Weber D, Liu F. Differential diagnosis of monoclonal gammopathies. *Arch Pathol Lab Med*. 1999;123:108-113.
29. Dimopoulos MA, Mouloupos LA, Delasalle K, Alexanian R. Solitary plasmacytoma of bone and asymptomatic multiple myeloma. *Hematol Oncol Clin North Am*. 1992;6:359-369.
30. Dimopoulos MA, Mouloupos LA, Smith T, Delasalle KB, Alexanian R. Risk of disease progression in asymptomatic multiple myeloma. *Am J Med*. 1993;94:57-61.
31. Riccardi A, Gobbi PG, Ucci G, et al. Changing clinical presentation of multiple myeloma. *Eur J Cancer*. 1991;27:1401-1405.
32. Wisloff F, Andersen P, Andersson TR, et al. Has the incidence of multiple myeloma in old age been underestimated? The myeloma project of health region I in Norway. I. *Eur J Haematol*. 1991;47:333-337.
33. Hjorth M, Hellquist L, Holmberg E, Magnusson B, Rodjer S, Westin J. Initial versus deferred melphalan-prednisone therapy for asymptomatic multiple myeloma stage I: a randomized study. *Eur J Haematol*. 1993;50:95-102.
34. Grignani G, Gobbi PG, Formisano R, et al. A prognostic index for multiple myeloma. *Br J Cancer*. 1996;73:1101-1107.
35. Dighiero G, Maloum K, Desablens B, et al. Chlorambucil in indolent chronic lymphocytic leukemia. *N Engl J Med*. 1998;338:1506-1514.
36. Wisloff F, Andersen P, Andersson TR, et al. Incidence and follow-up of asymptomatic multiple myeloma. *Eur J Haematol*. 1991;47:338-341.
37. Facon T, Menard JF, Michaux JL, et al. Prognostic factors in low tumor mass asymptomatic myeloma. *Am J Hematol*. 1995;48:71-75.
38. Greipp PR, Kyle RA. Clinical, morphological, and cell kinetic differences among multiple myeloma, monoclonal gammopathy of undetermined significance, and smoldering multiple myeloma. *Blood*. 1983;62:166-171.
39. Witzig TE, Gonchoroff NJ, Katzmann JA, Therneau TM, Kyle RA, Greipp PR. Peripheral blood B cell labeling indices are a measure of disease activity in patients with monoclonal gammopathies. *J Clin Oncol*. 1988;6:1041-1046.
40. Witzig TE, Kyle RA, O'Fallon WM, Greipp PR. Detection of peripheral blood plasma cells as a predictor of disease course in patients with smoldering multiple myeloma. *Br J Haematol*. 1994;87:266-272.
41. Mouloupos LA, Dimopoulos MA, Smith TL, et al. Prognostic significance of magnetic resonance imaging in patients with asymptomatic multiple myeloma. *J Clin Oncol*. 1995;13:251-256.
42. Vande Berg BC, Lecouvet FE, Michaux L, et al. Stage I multiple myeloma: value of MR imaging of the bone marrow in the determination of prognosis. *Radiology*. 1996;201:243-246.
43. Mariette X, Zagdanski AM, Guermazi A, et al. Prognostic value of vertebral lesions detected by magnetic resonance imaging in patients with stage I multiple myeloma. *Br J Haematol*. 1999;104:723-729.
44. Weber DM, Dimopoulos MA, Mouloupos LA, Delasalle KB, Smith T, Alexanian R. Prognostic features of asymptomatic multiple myeloma. *Br J Haematol*. 1997;97:810-814.
45. Avet-Loiseau H, Li J-Y, Morineau N, et al. On behalf of the Intergroupe Francophone du Myeloma: monosomy 13 is associated with the transition of monoclonal gammopathy of undetermined significance to multiple myeloma. *Blood*. 1999;94:2583-2589.
46. Avet-Loiseau H, Facon T, Daviet A, et al. 14q32 translocations and monosomy 13 observed in monoclonal gammopathy of undetermined significance delineate a multistep process for the oncogenesis of multiple myeloma. *Cancer Res*. 1999;59:4546-4550.

47. Kyle RA, Beard CM, O'Fallon M, Kurland LT. Incidence of multiple myeloma in Olmsted County, Minnesota: 1978 through 1990, with a review of the trend since 1945. *J Clin Oncol*. 1994;12:1577-1583.
48. Calasanz MJ, Cigudosa JC, Odero MD, et al. Cytogenetic analysis of 280 patients with multiple myeloma and related disorders: primary breakpoints and clinical correlations. *Genes Chromosomes Cancer*. 1997;18:84-93.
49. Fonseca R, Aguayo P, Ahmann GJ, et al. Translocations at 14q32 are common in patients with the monoclonal gammopathy of undetermined significance (MGUS) and involve several partner chromosomes [abstract]. *Blood*. 1999;94:663a.
50. Shou Y, Martelli ML, Gabrea A, Qi Y, et al. Diverse karyotypic abnormalities of the c-myc locus associated with c-myc dysregulation and tumor progression in multiple myeloma. *Proc Natl Acad Sci U S A*. 2000;97:228-233.
51. Smadja NV, Fruchart C, Isnard F, et al. Chromosomal analysis in multiple myeloma: cytogenetic evidence of two different diseases. *Leukemia*. 1998;12:960-969.
52. Drach J, Angerler J, Schuster J, et al. Interphase fluorescence in situ hybridization identifies chromosomal abnormalities in plasma cells from patients with monoclonal gammopathy of undetermined significance. *Blood*. 1995;86:3915-3921.
53. Bataille R, Jourdan M, Zhang XG, Klein B. Serum levels of interleukin 6, a potent myeloma cell growth factor, as a reflect of disease severity in plasma cell dyscrasias. *J Clin Invest*. 1989;84:2008-2011.
54. Barille S, Thabard W, Robillard N, et al. CD130 rather than CD126 expression is associated with disease activity in multiple myeloma. *Br J Haematol*. 1999;106:532-535.
55. Kyrtonis MC, Dedoussis G, Zervas C, et al. Soluble interleukin-6 receptor (sIL-6R), a new prognostic factor in multiple myeloma. *Br J Haematol*. 1996;93:398-400.
56. Thabard W, Barille S, Collette M, et al. Myeloma cells release soluble interleukin-6R- α in relation to disease progression by two distinct mechanisms: alternative splicing and proteolytic cleavage. *Clin Cancer Res*. 1999;5:2693-2697.
57. Sati I, Greaves M, Apperley JF, Russel RG, Croucher PI. Expression of interleukin-1 β and tumour necrosis factor- α in plasma cells from patients with multiple myeloma. *Br J Haematol*. 1999;104:350-357.
58. Lacy MQ, Donovan KA, Heimbach JK, Ahman GJ, Lust JA. Comparison of interleukin-1 β expression by in situ hybridization in monoclonal gammopathy of undetermined significance and multiple myeloma. *Blood*. 1999;93:300-305.
59. Klein B, Lu ZY, Gu ZJ, Castes V, Jourdan M, Rossi JF. Interleukin-10 and GP 130 cytokines in human multiple myeloma. *Leuk Lymphoma*. 1999;34:63-70.
60. Ocqueteau M, Orfao A, Almeida J, et al. Immunophenotypic characterization of plasma cells from monoclonal gammopathy of undetermined significance patients. Implications for the differential diagnosis between MGUS and multiple myeloma. *Am J Pathol*. 1998;152:1655-1665.
61. van Driel M, Gunthert U, Stauder R, Joling P, Lokhorst HM, Bloem AC. CD44 isoforms distinguish between bone marrow plasma cells from normal individuals and patients with multiple myeloma at different stages of disease. *Leukemia*. 1998;12:1821-1828.
62. Sonneveld P, Durie BG, Lockhorst HM, Frutiger Y, Shoester M, Vela EE. Analysis of multidrug resistance (MDR-1) glycoprotein and CD56 expression to separate monoclonal gammopathy from multiple myeloma. *Br J Haematol*. 1993;83:63-67.
63. Vacca A, Ribatti D, Roncali L, Serio G, Silvestris F, Dammaco F. Bone marrow angiogenesis and progression in multiple myeloma. *Br J Haematol*. 1994;87:503-508.
64. Vacca A, Ribatti D, Presta M, et al. Bone marrow neovascularization plasma cell angiogenic potential and matrix metalloproteinase-2 secretion parallel progression of human multiple myeloma. *Blood*. 1999;93:3064-3073.
65. Di Raimondo F, Giustolisi R, Azzaro MP, Sortino G, Palumbo GA, Bagnato S. Vascular endothelial growth factor (VEGF) in peripheral blood and bone marrow of multiple myeloma patients. VII International Myeloma Workshop, September 1-5, 1999; Stockholm, Sweden. Abstract 74, 115.
66. Singhal S, Mehta J, Desikon R, et al. Antitumor activity of thalidomide in refractory multiple myeloma. *N Engl J Med*. 1999;341:1565-1571.
67. Shima Y, Treon SP, Yorhizaki K, et al. Clinical and biological activity of thalidomide (THAL) in multiple myeloma (MM) [abstract]. *Blood*. 1999;94:125a.
68. Witzig TE, Timm M, Larson D, Greipp PR. Measurement of apoptosis and proliferation of bone marrow plasma cells in patients with plasma cell proliferation disorders. *Br J Haematol*. 1999;104:131-137.
69. Bataille R, Chappard D, Basle MF. Quantifiable excess of bone resorption in monoclonal gammopathy is an early symptom of malignancy: a prospective study of 87 bone biopsies. *Blood*. 1996;87:4762-4769.
70. Kyrtonis MC, Mouzaki A, Maniatis A. Mechanisms of polyclonal hypogammaglobulinemia in multiple myeloma. *Med Oncol*. 1999;16:73-77.
71. Paglieroni T, MacKenzie M, Gaggiano V. Abnormalities in immuno-regulatory CD5⁺ B cells precede the diagnosis of multiple myeloma. *Ann N Y Acad Sci*. 1992;651:486-487.